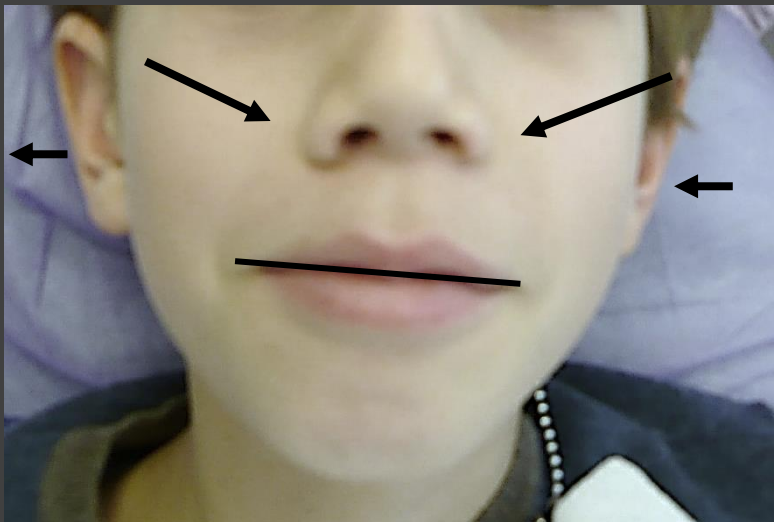
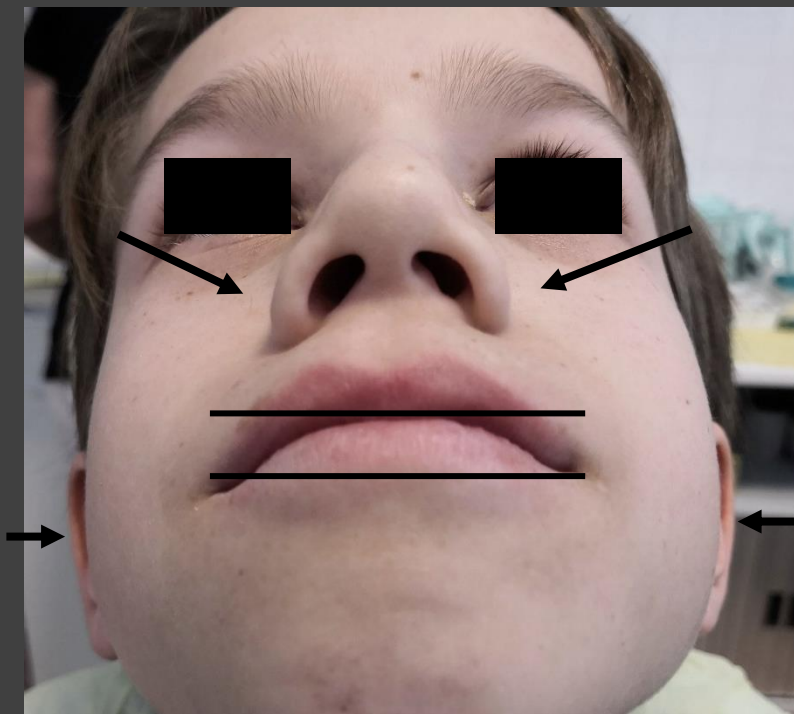

START USING FROGGY MOUTH



START USING FROGGY MOUTH

FOLLOW UP 25 MONTHS

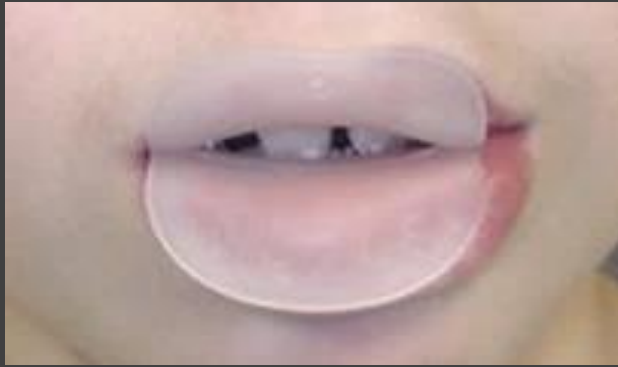

FOLLOW UP 25 MONTHS

CASE 4



CLASS III
ANTERIOR CROSSBITE
RIGHT SIDE CROSSBITE

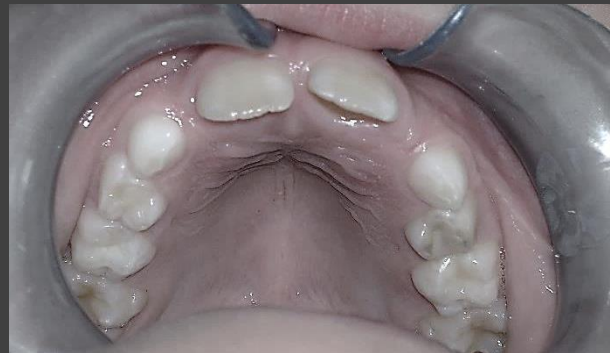
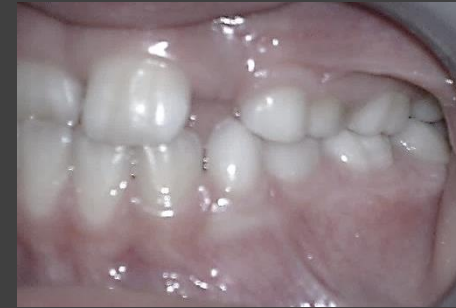
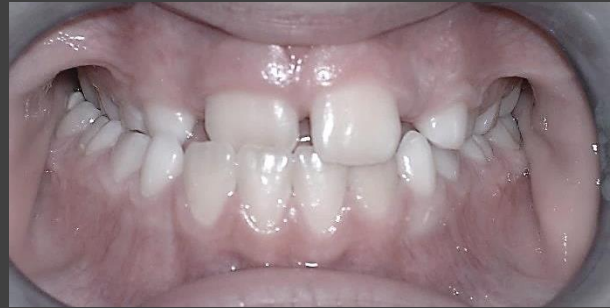
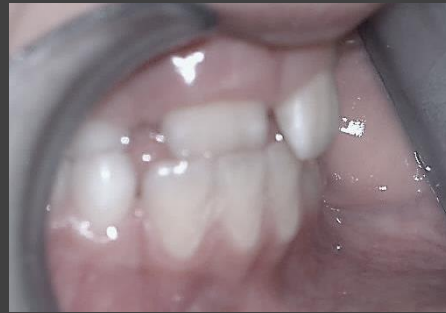
B.L

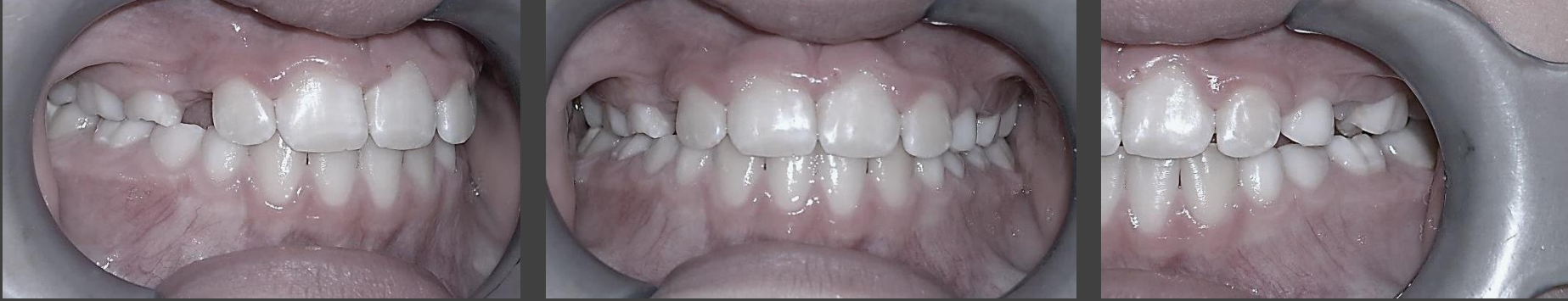

7-YEARS-OLD MALE

TYPE OF DEGLUTITION :SUCKING-DEGLUTITION

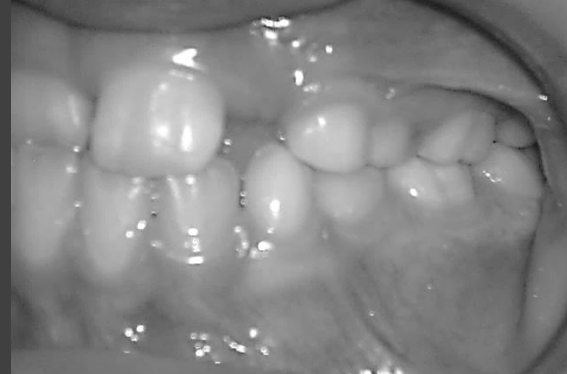
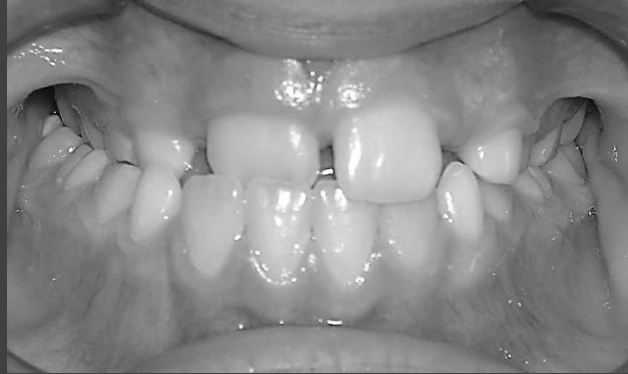
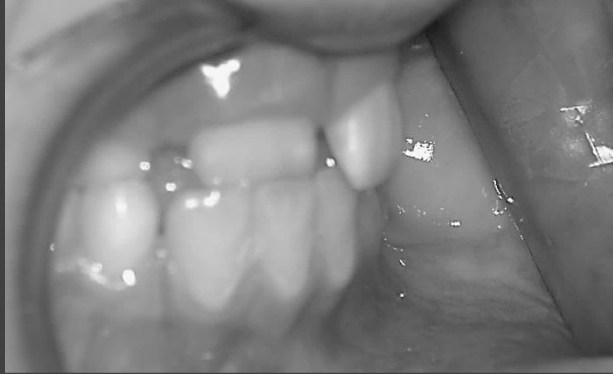START USING FROGGY MOUTH

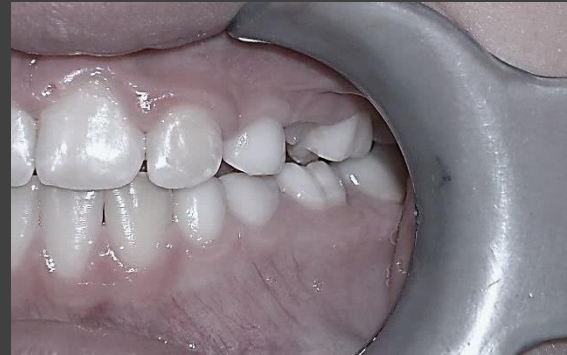
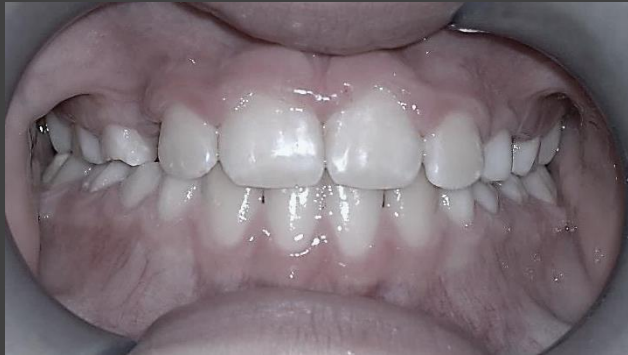
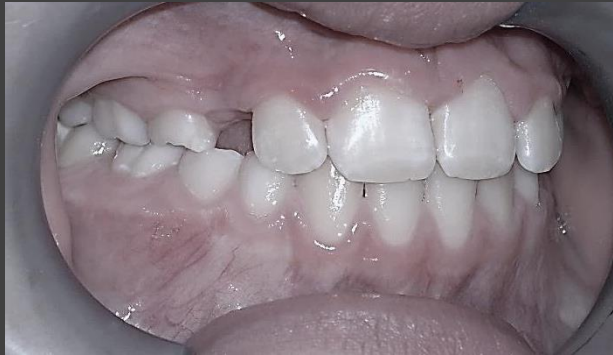AFTER 17 MONTHS

DR. PIETRO MANZINI
ORTHODONTIC SPECIALIST



START USING FROGGY MOUTH



AFTER 17 MONTHS

DR. PIETRO MANZINI
ORTHODONTIC SPECIALIST