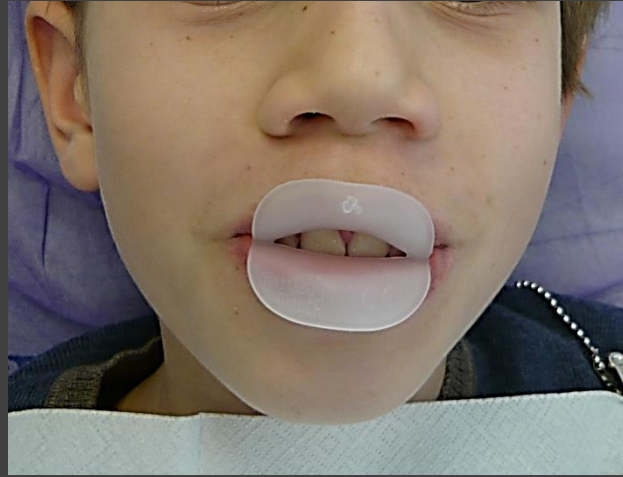

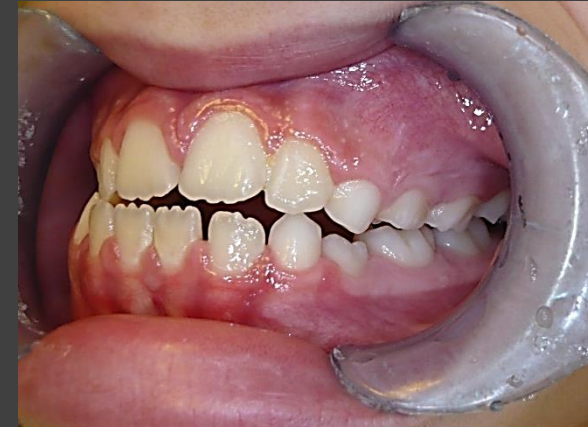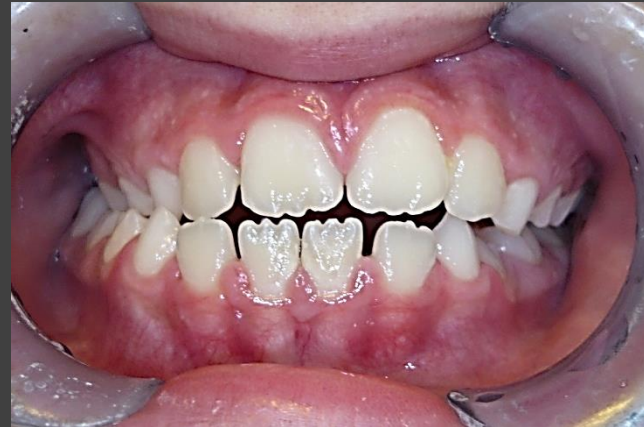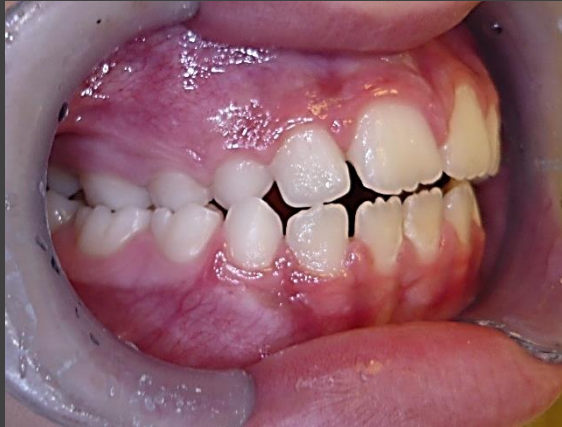CASE 37

RIGHT SIDE CROSSBITE

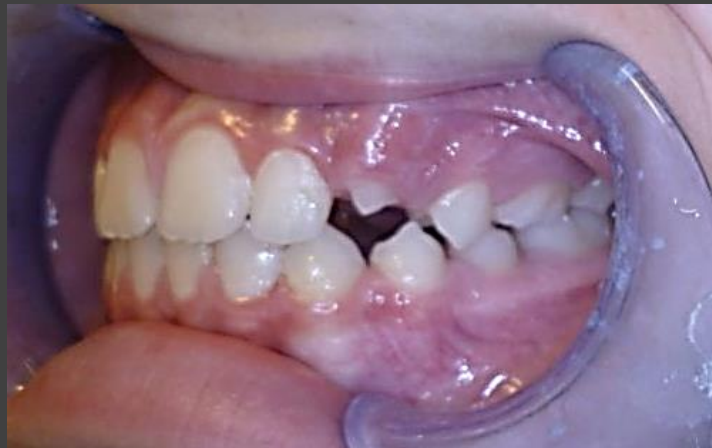
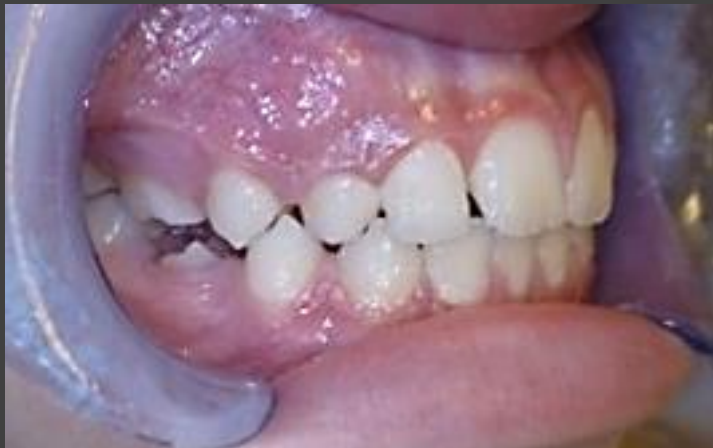
**FIL.
MALE
AGE:11 YEARS**

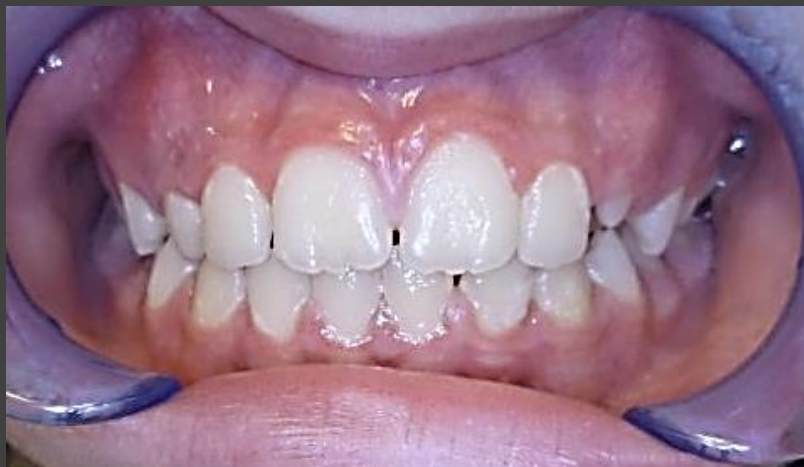TYPE OF DEGLUTITION :SUCKING-DEGLUTITION



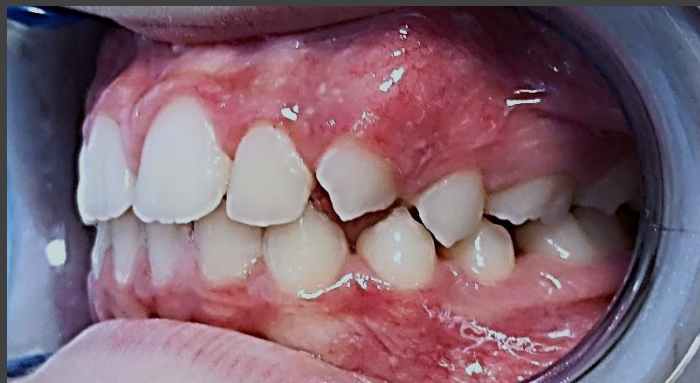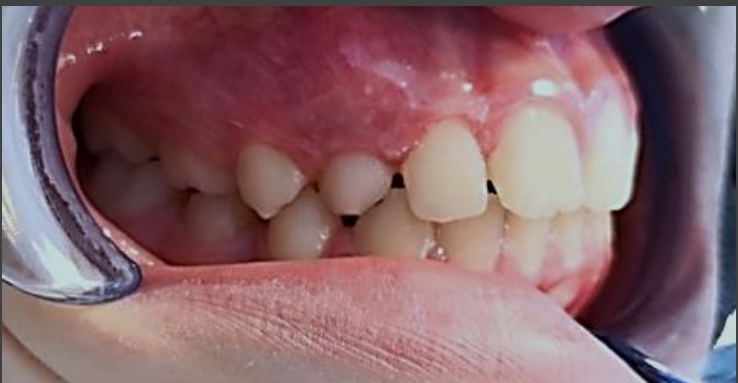START USING FROGGY MOUTH



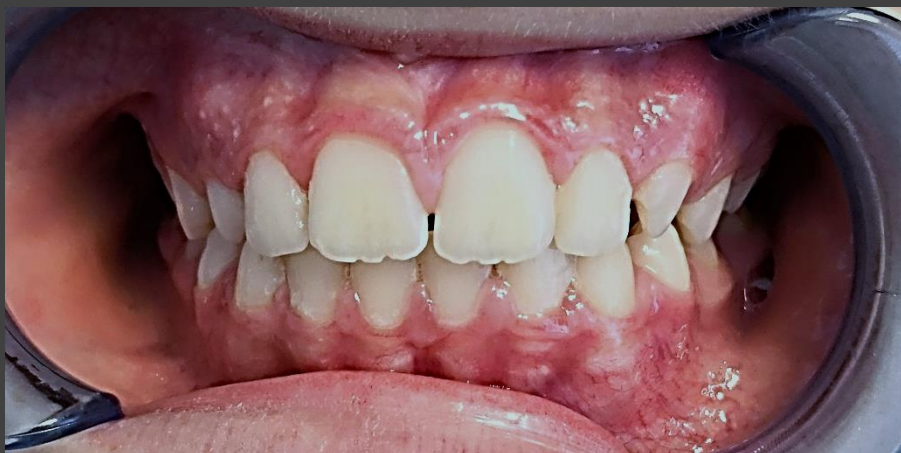10 MONTH LATER
THE END USING FROGGY MOUTH



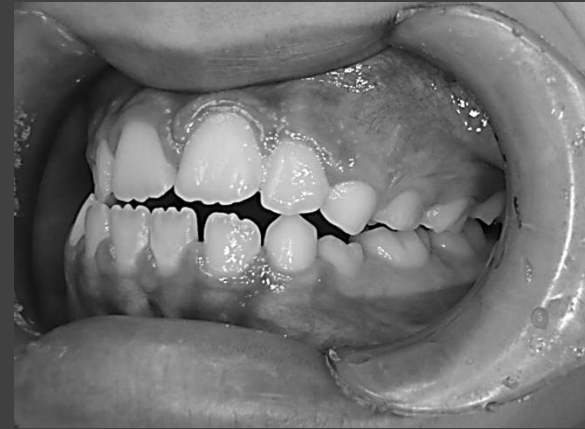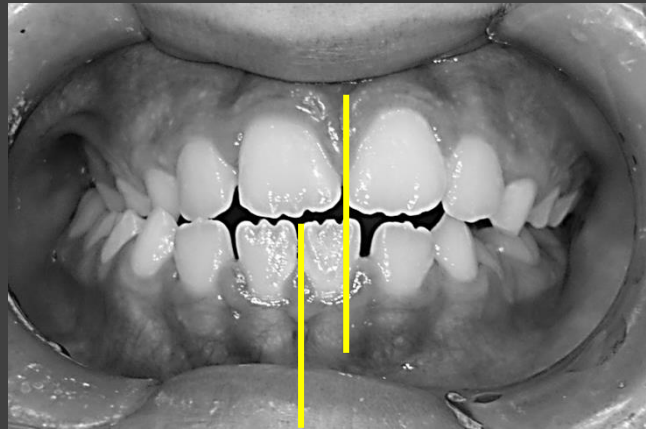
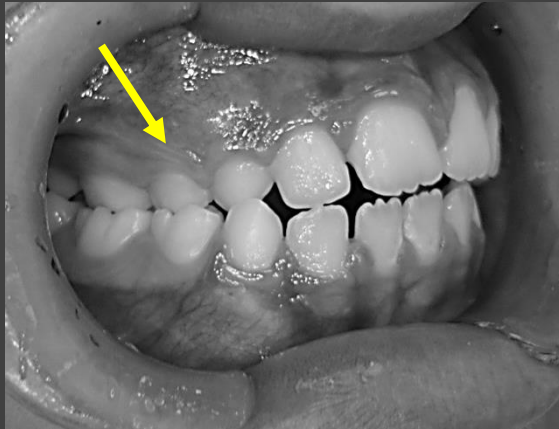
DR. PIETRO MANZINI
ORTHODONTIC SPECIALIST



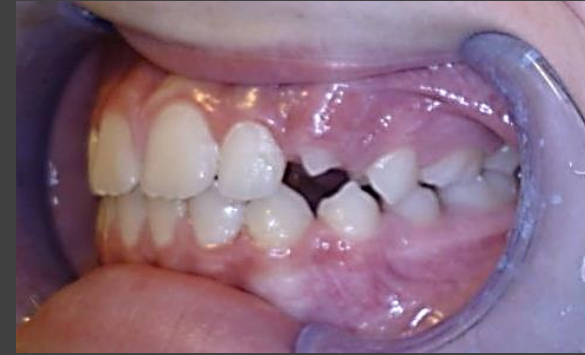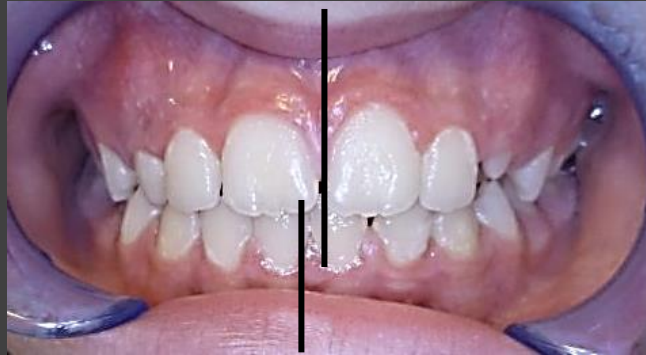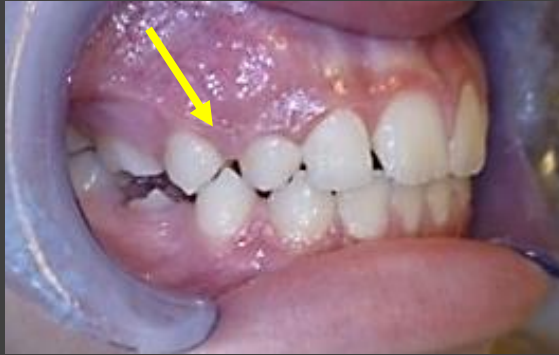FOLLOW UP 15 MONTHS



DR. PIETRO MANZINI
ORTHODONTIC SPECIALIST

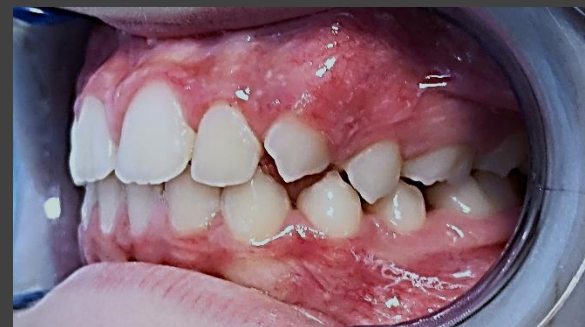
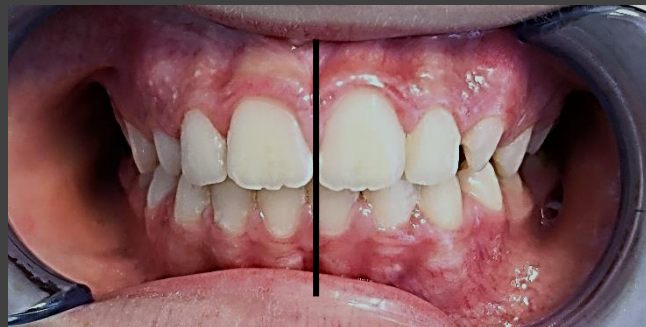
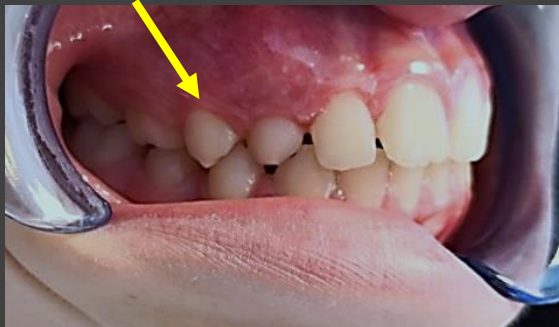START USING FROGGY MOUTH



10 MONTH LATER

THE END USING FROGGY MOUTH



FOLLOW UP 15 MONTHS